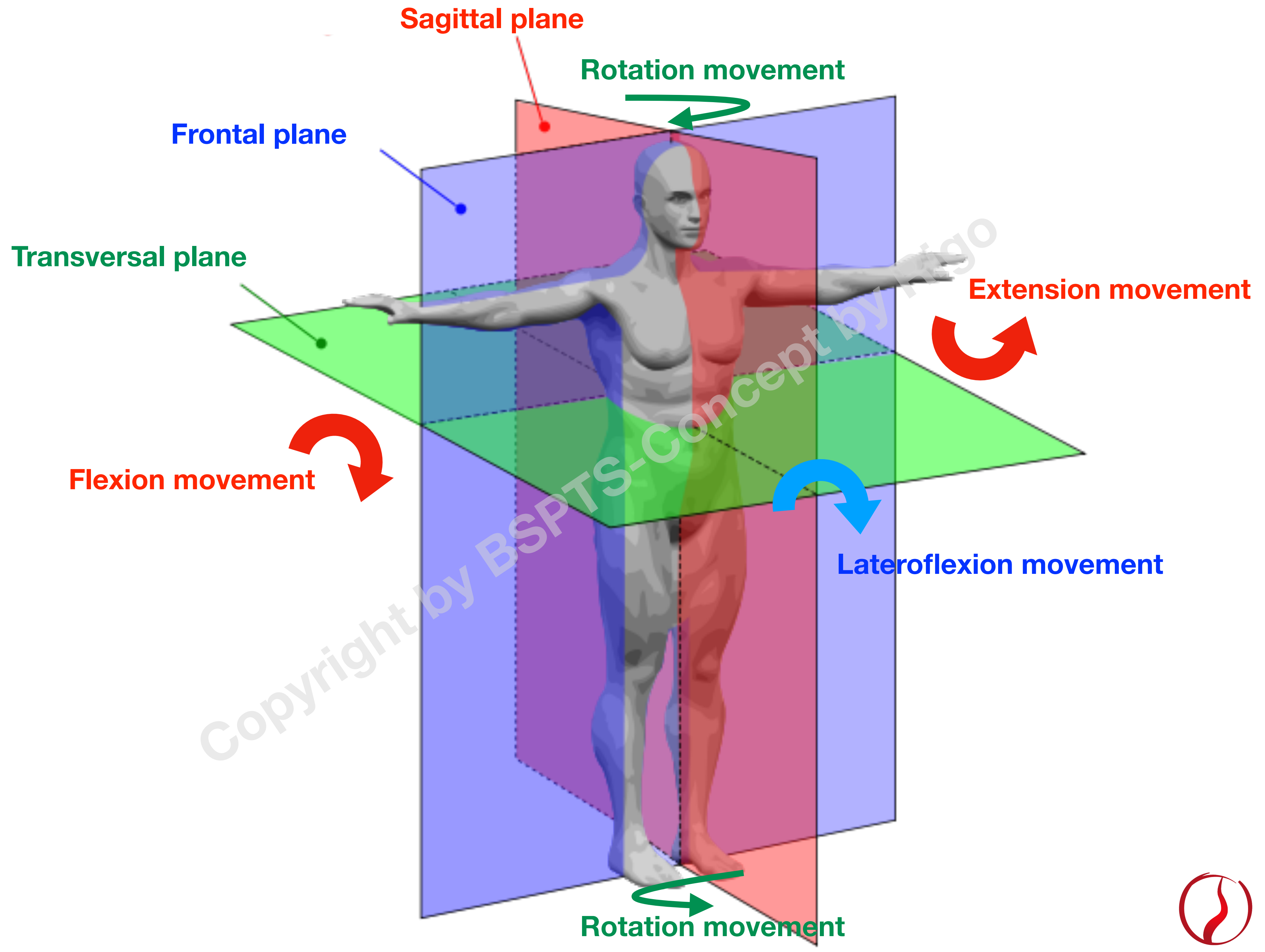
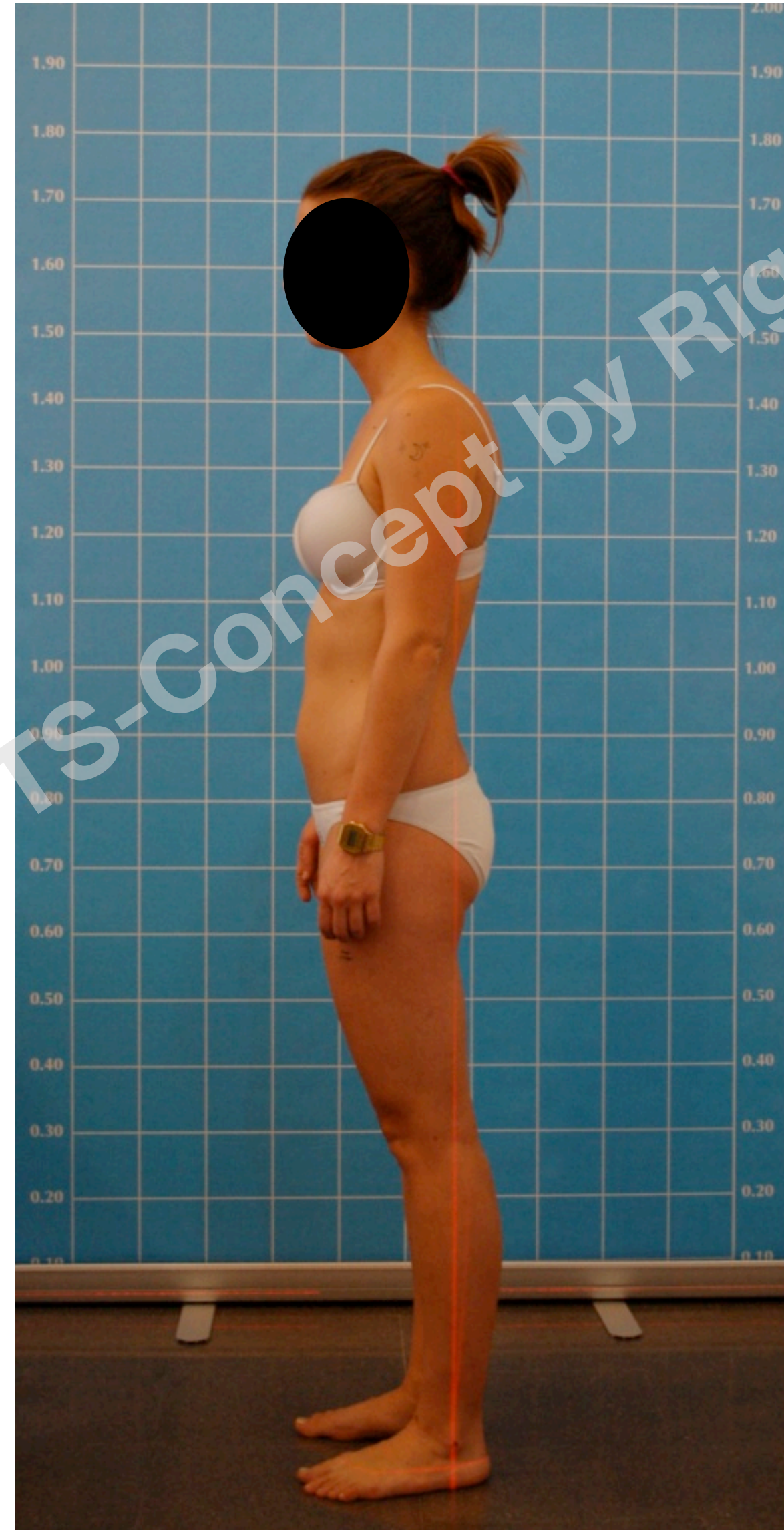
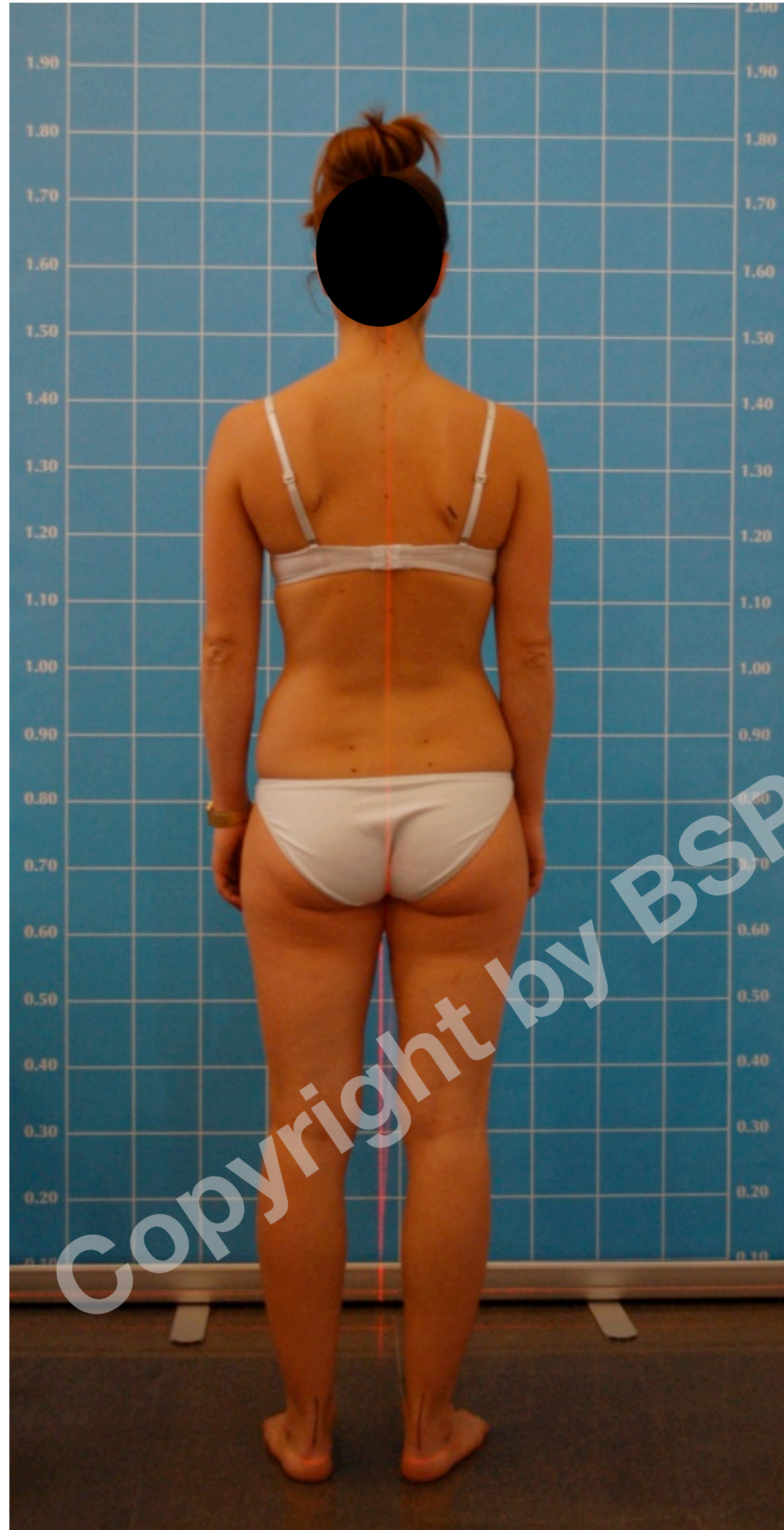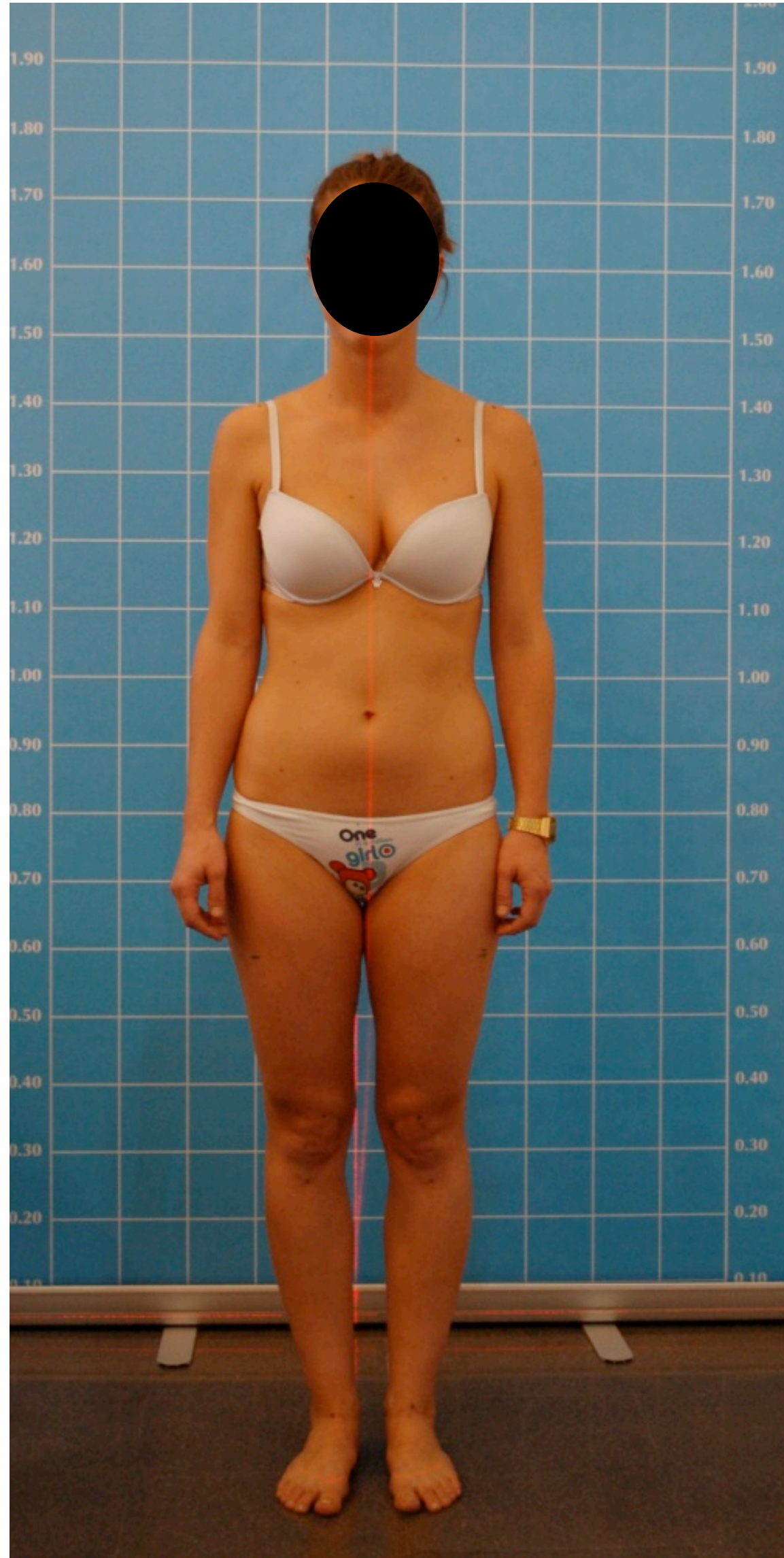

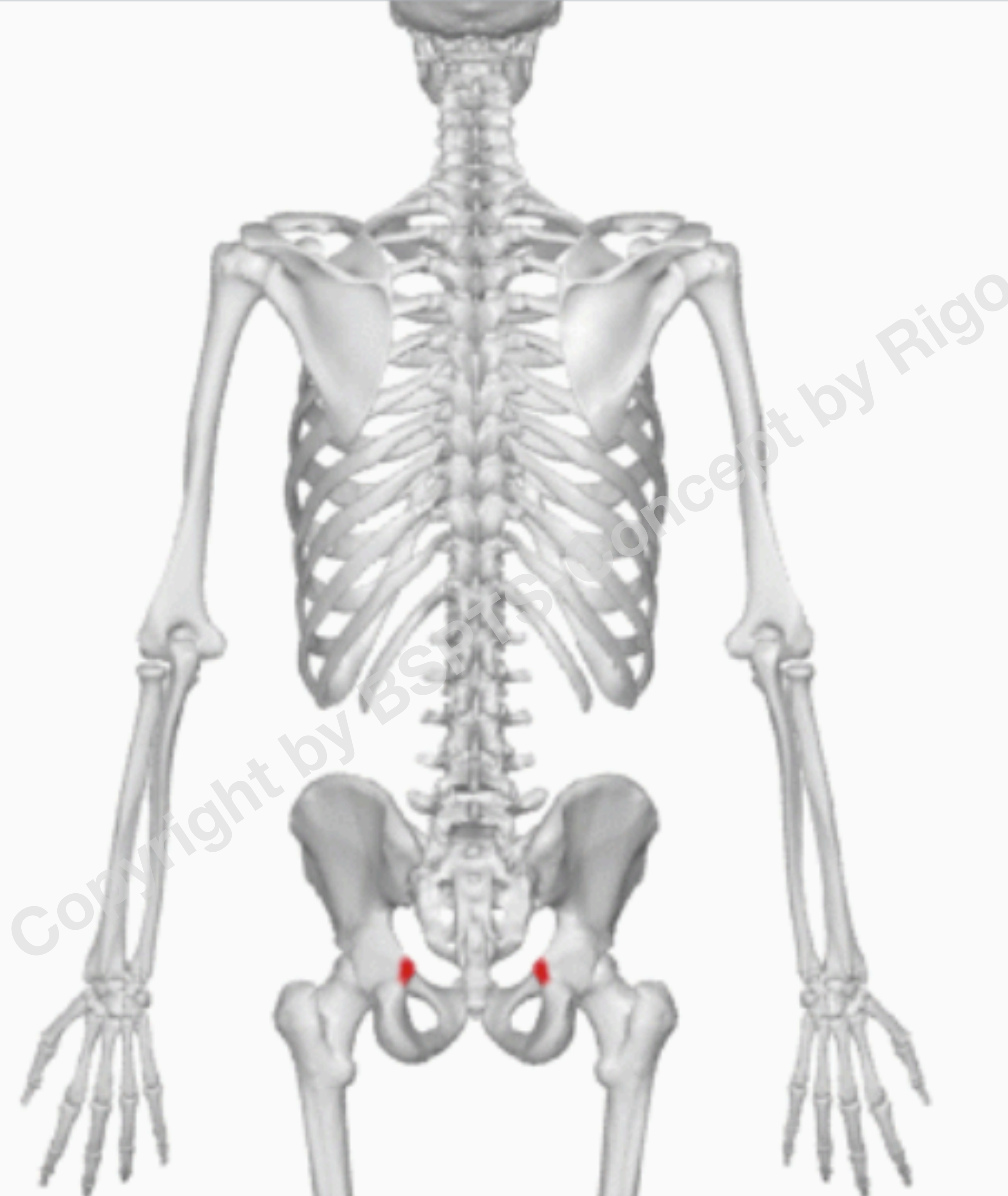
Anatomía de la Columna Vertebral

Planos y Ejes





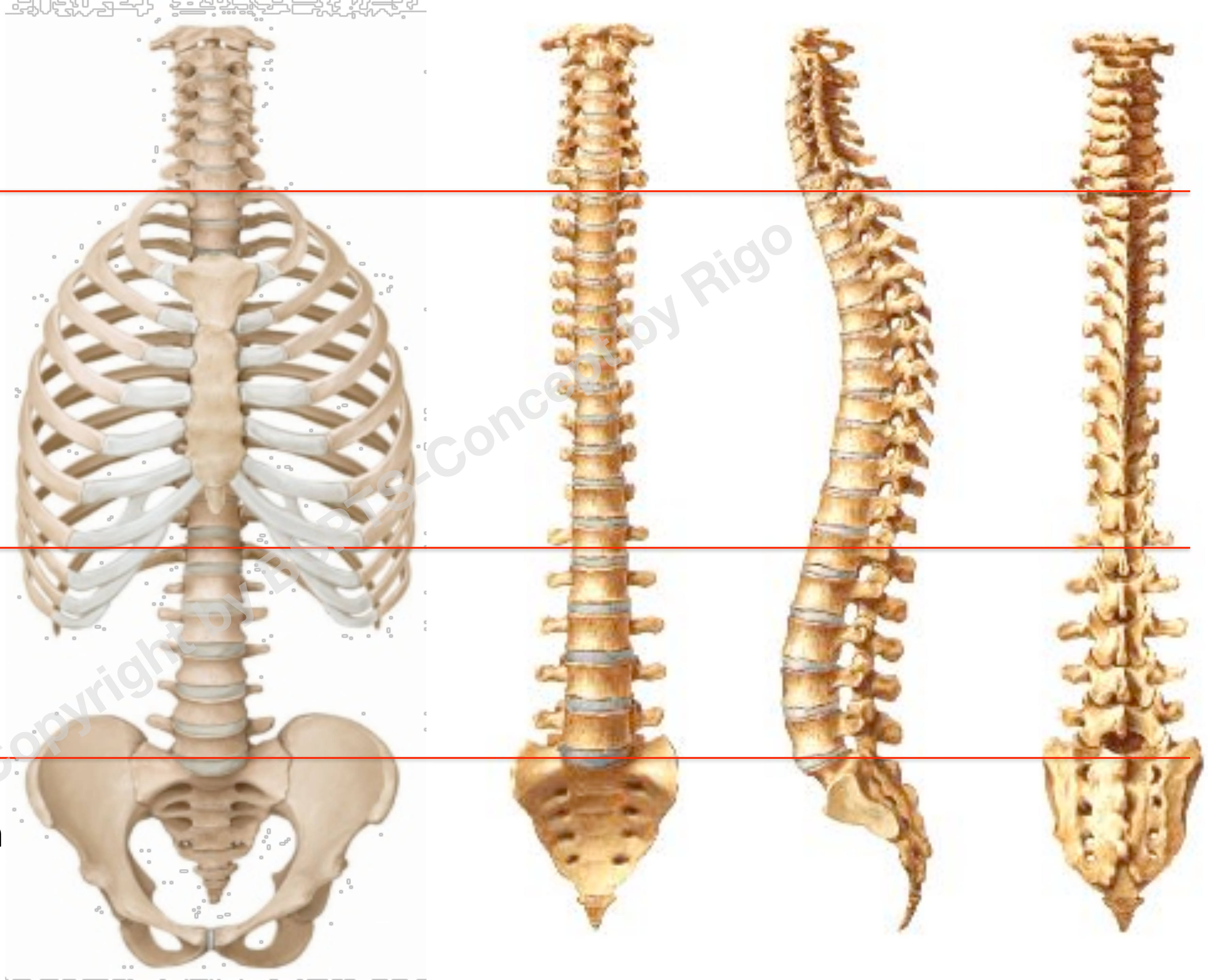

Cervical Region

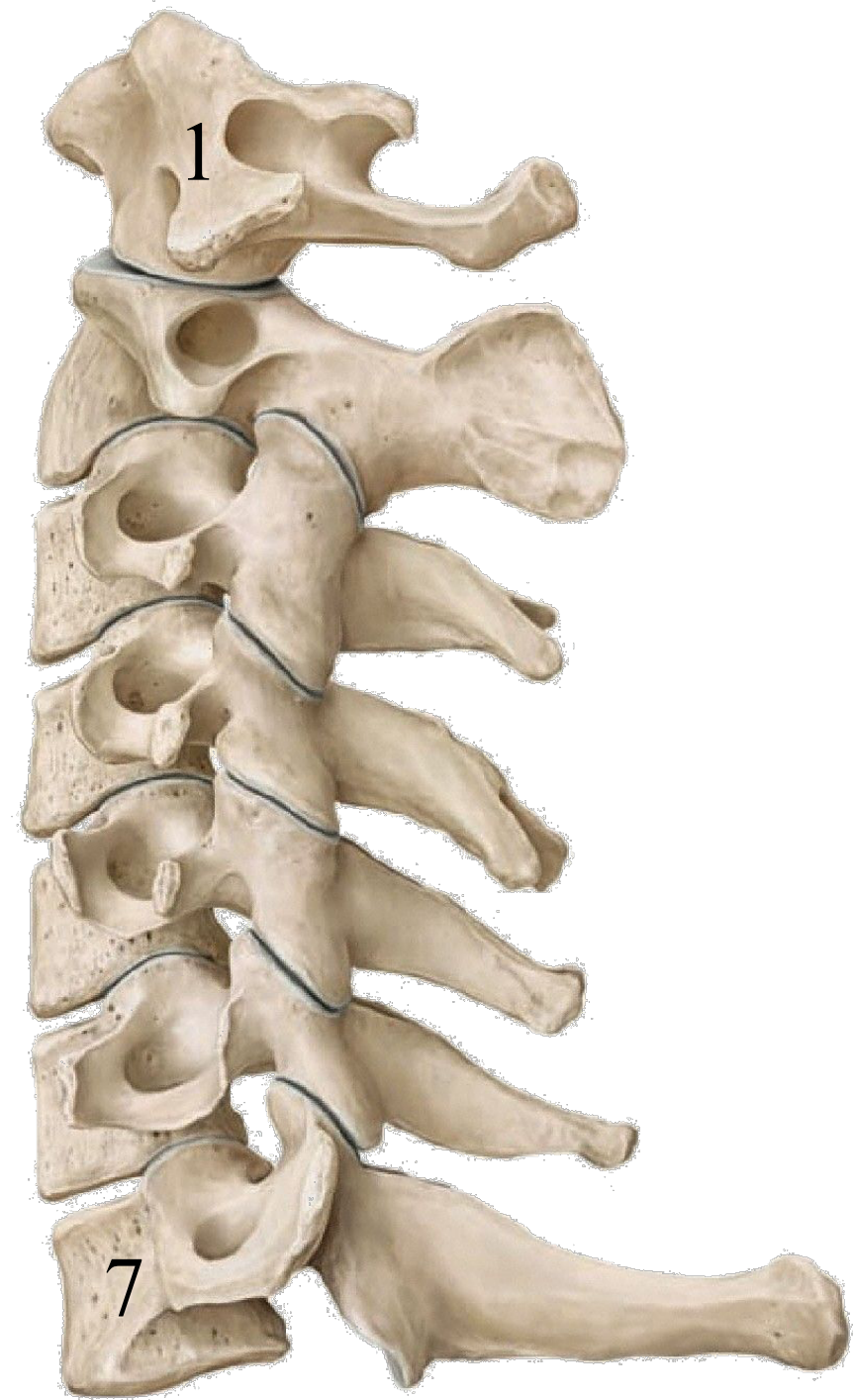
Thoracic Region

Lumbar Region

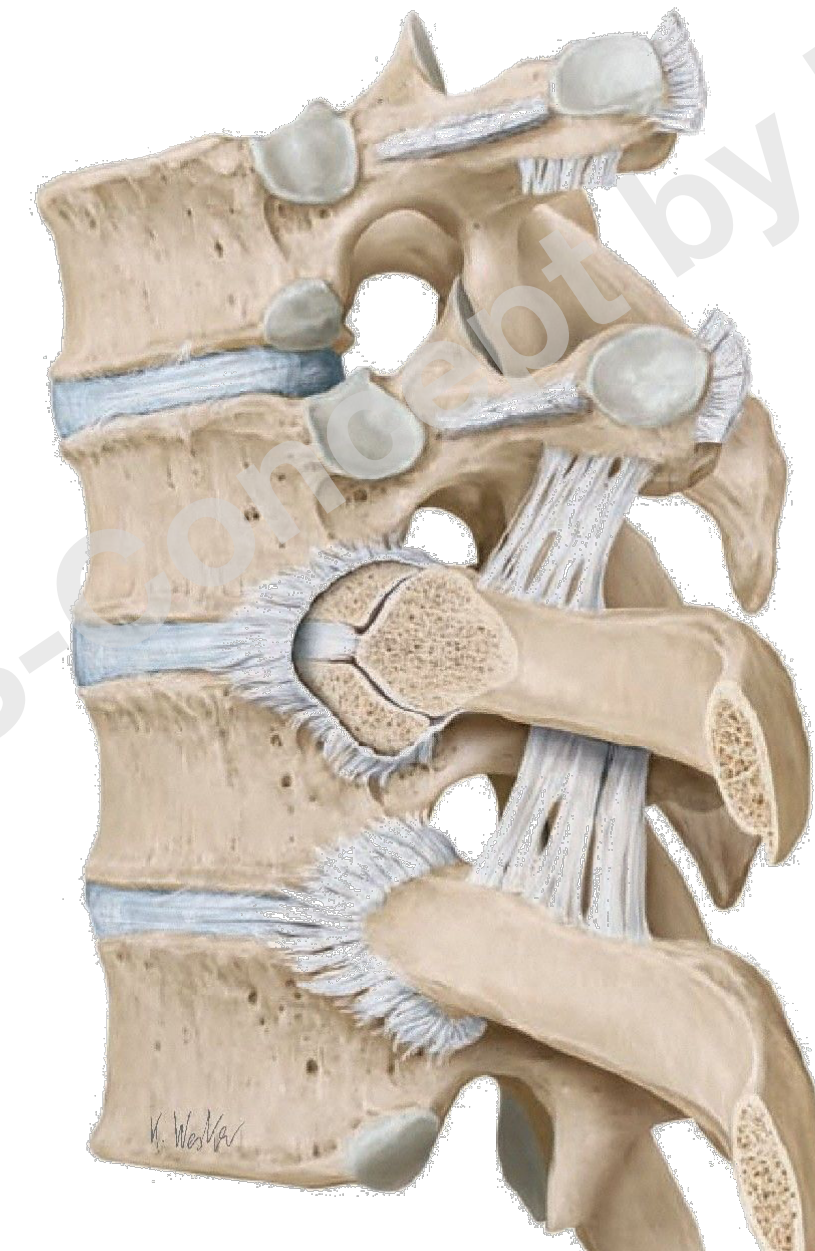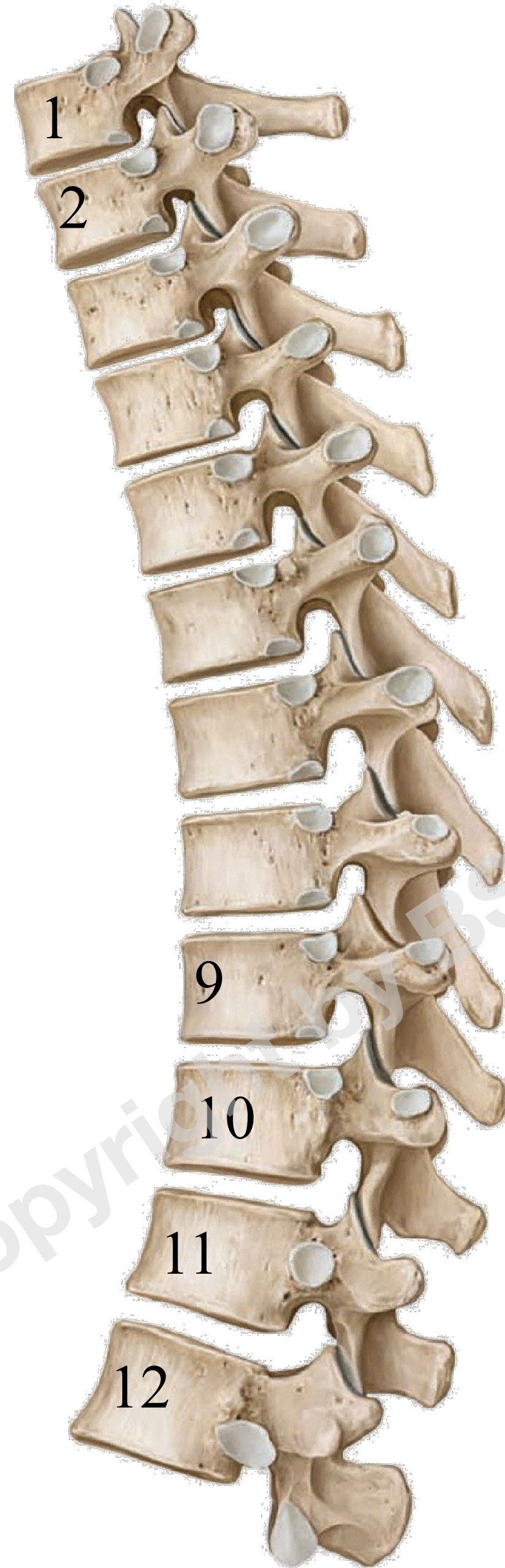
Pelvis & Sacrum



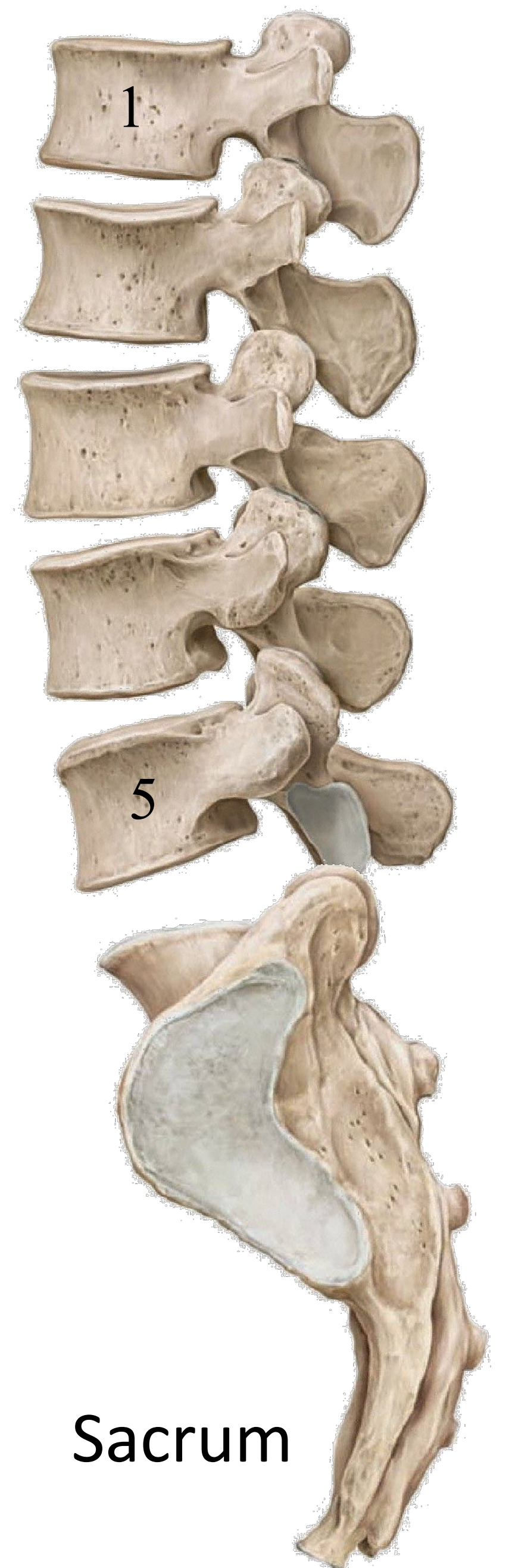
Cervical



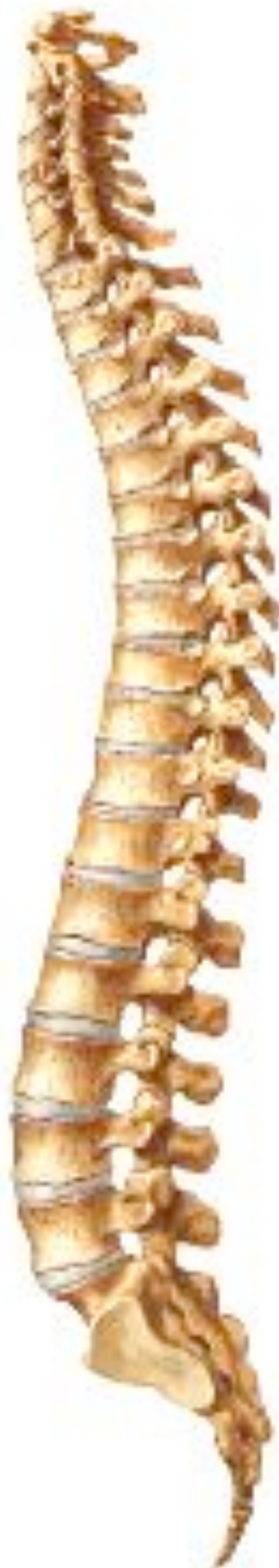Thoracic



Lumbar



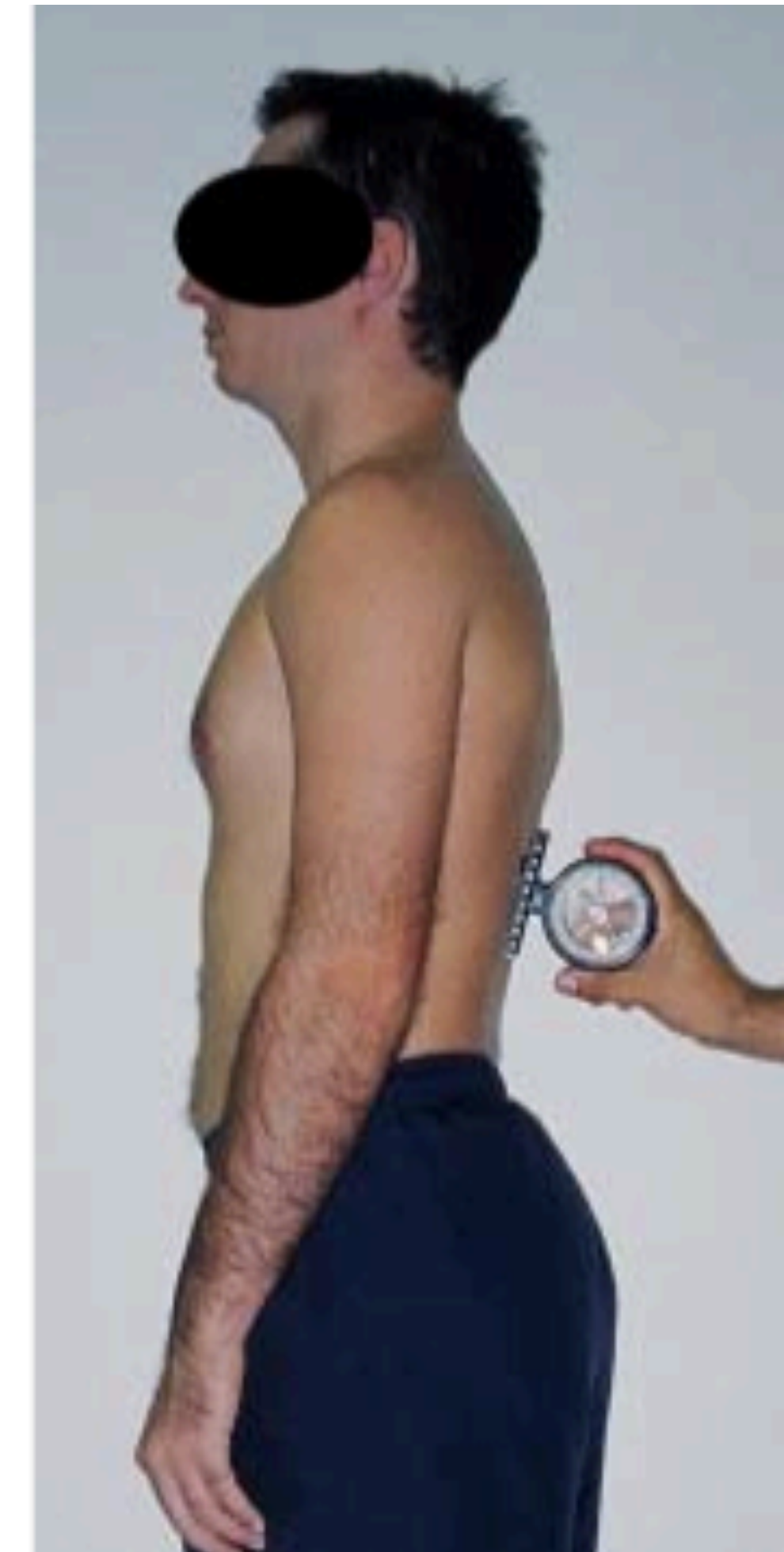
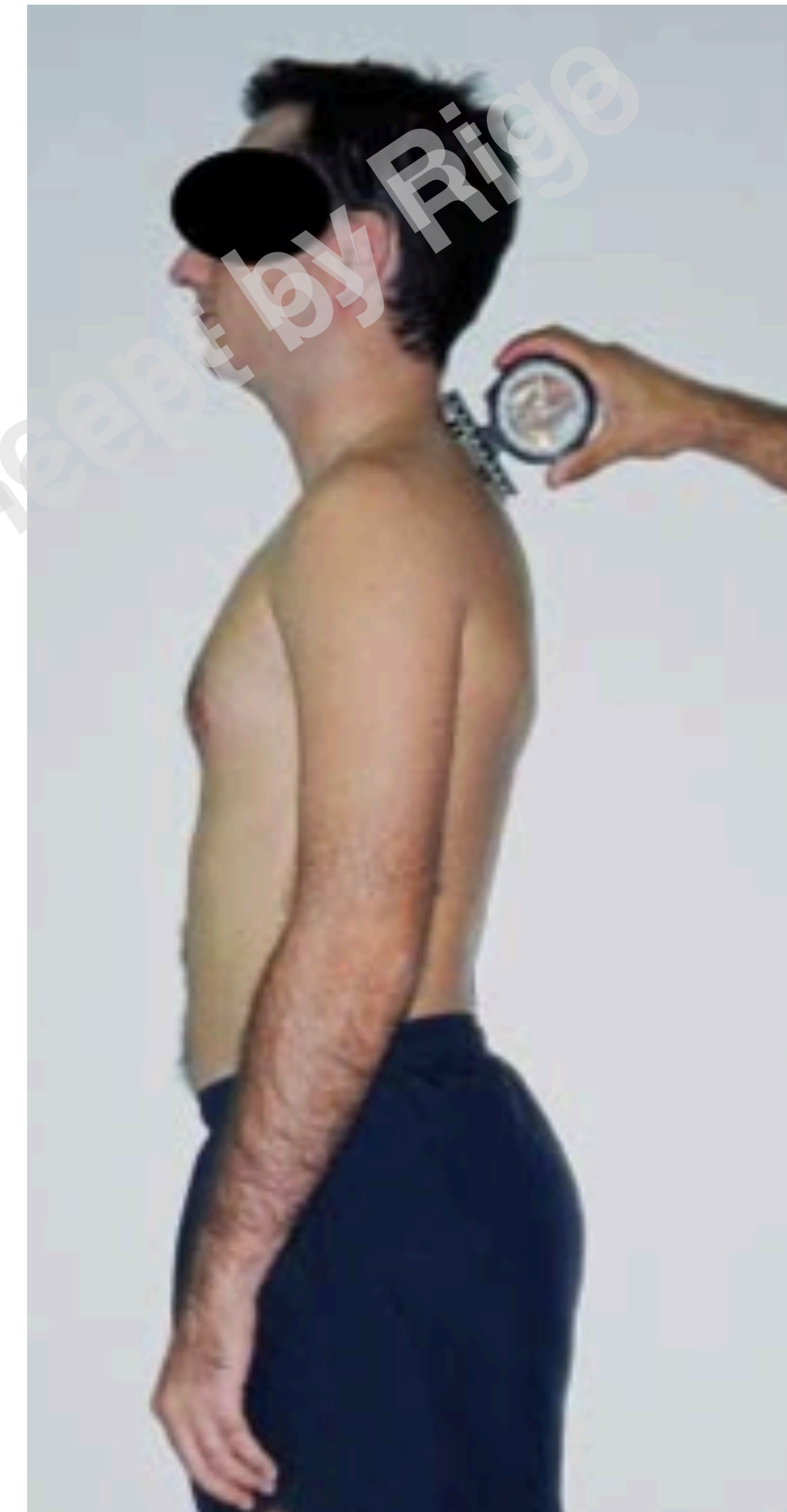
Sacrum

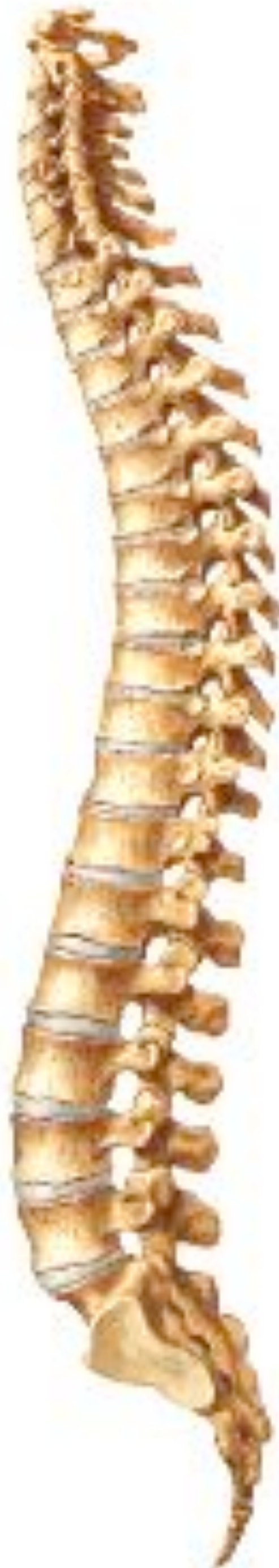

Región Dorsal

Cifosis Torácica

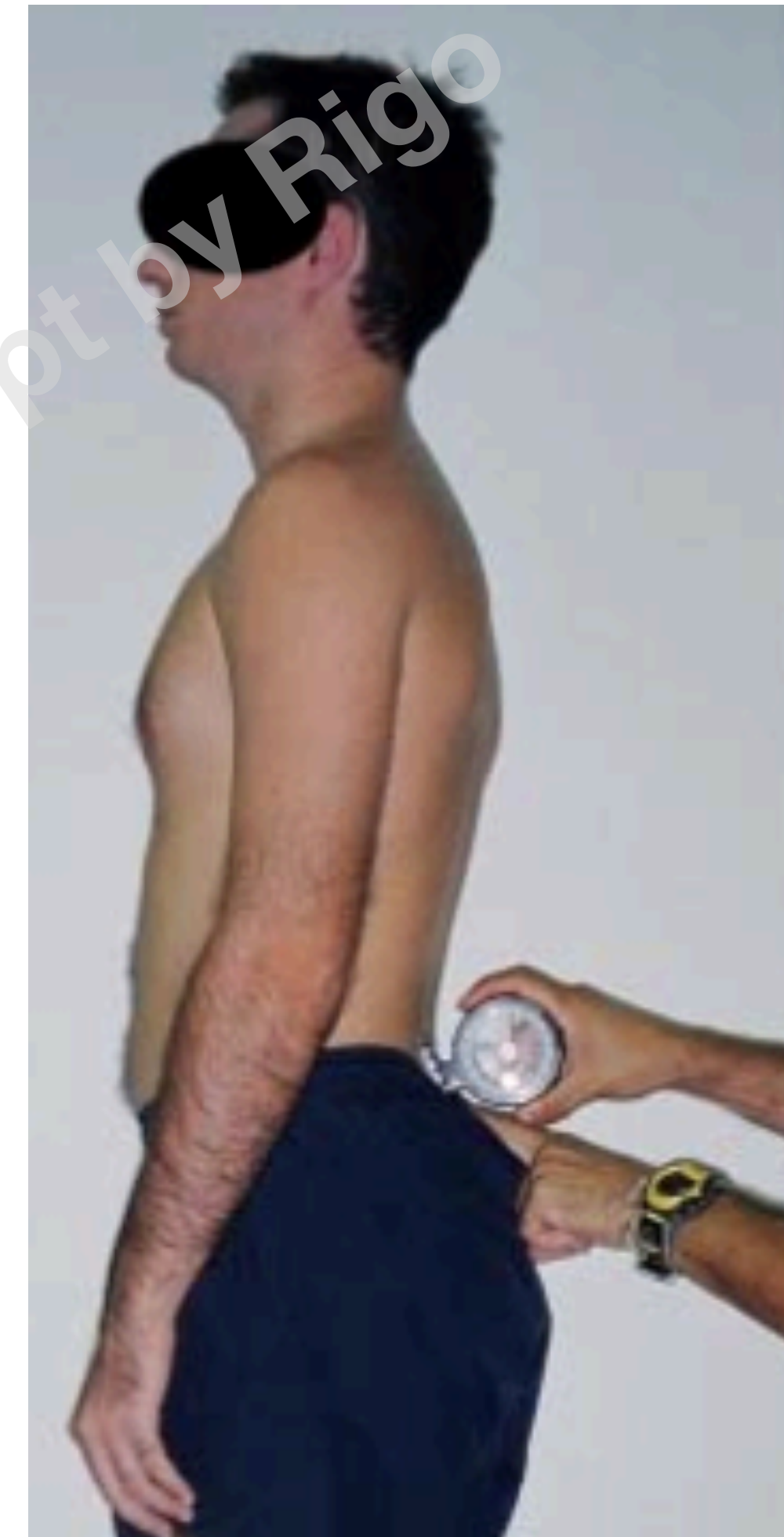
Rectificación	$< 20^{\circ}$
Normalidad	20-45
Hipercifosis leve	46-60
Hipercifosis moderada	>61

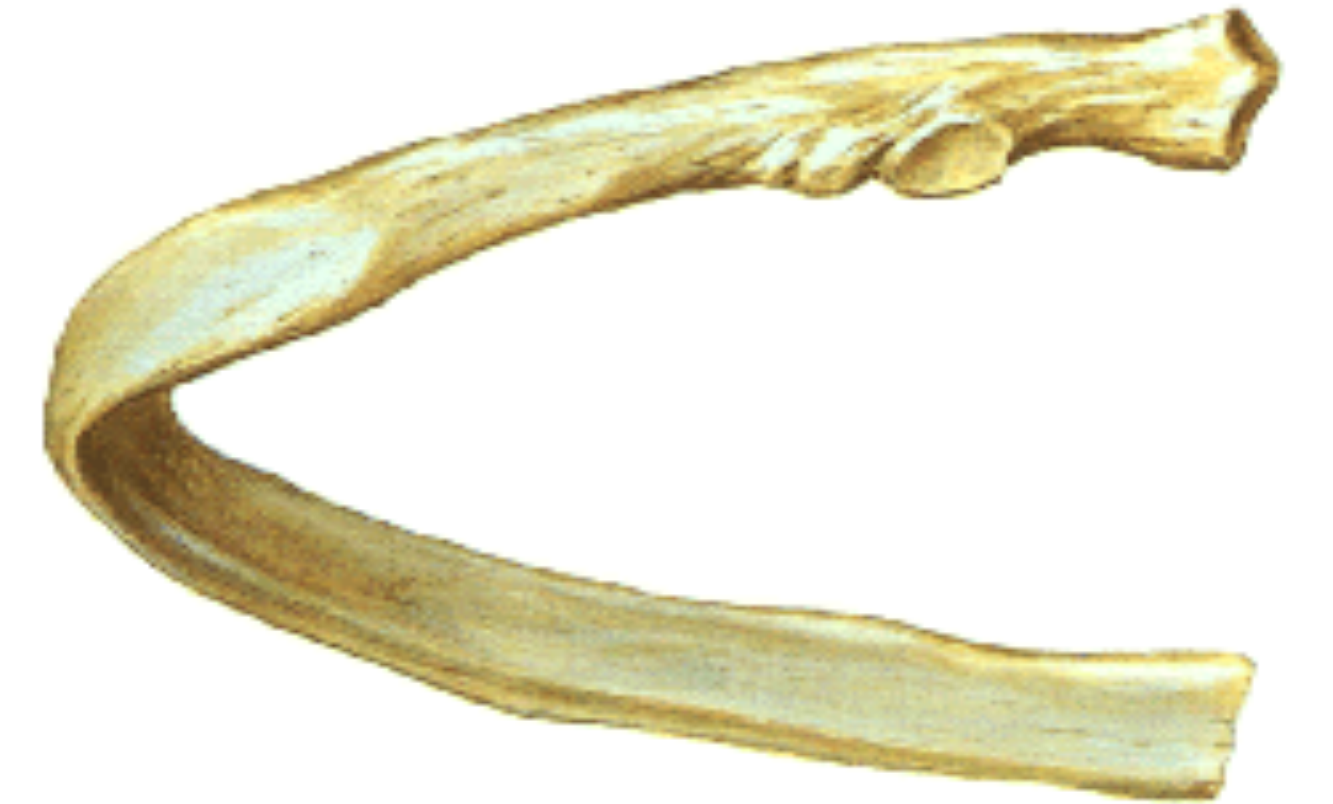
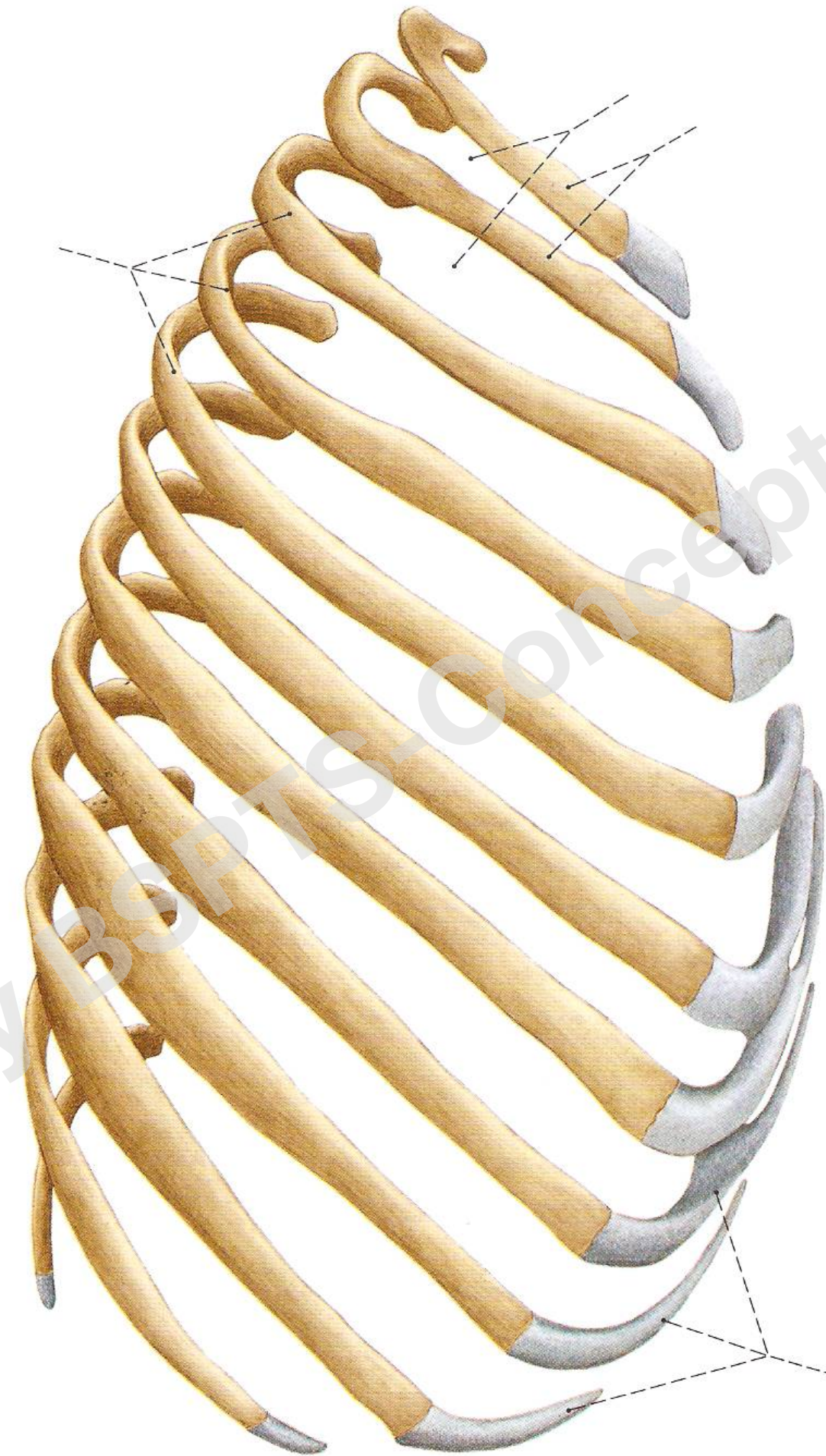
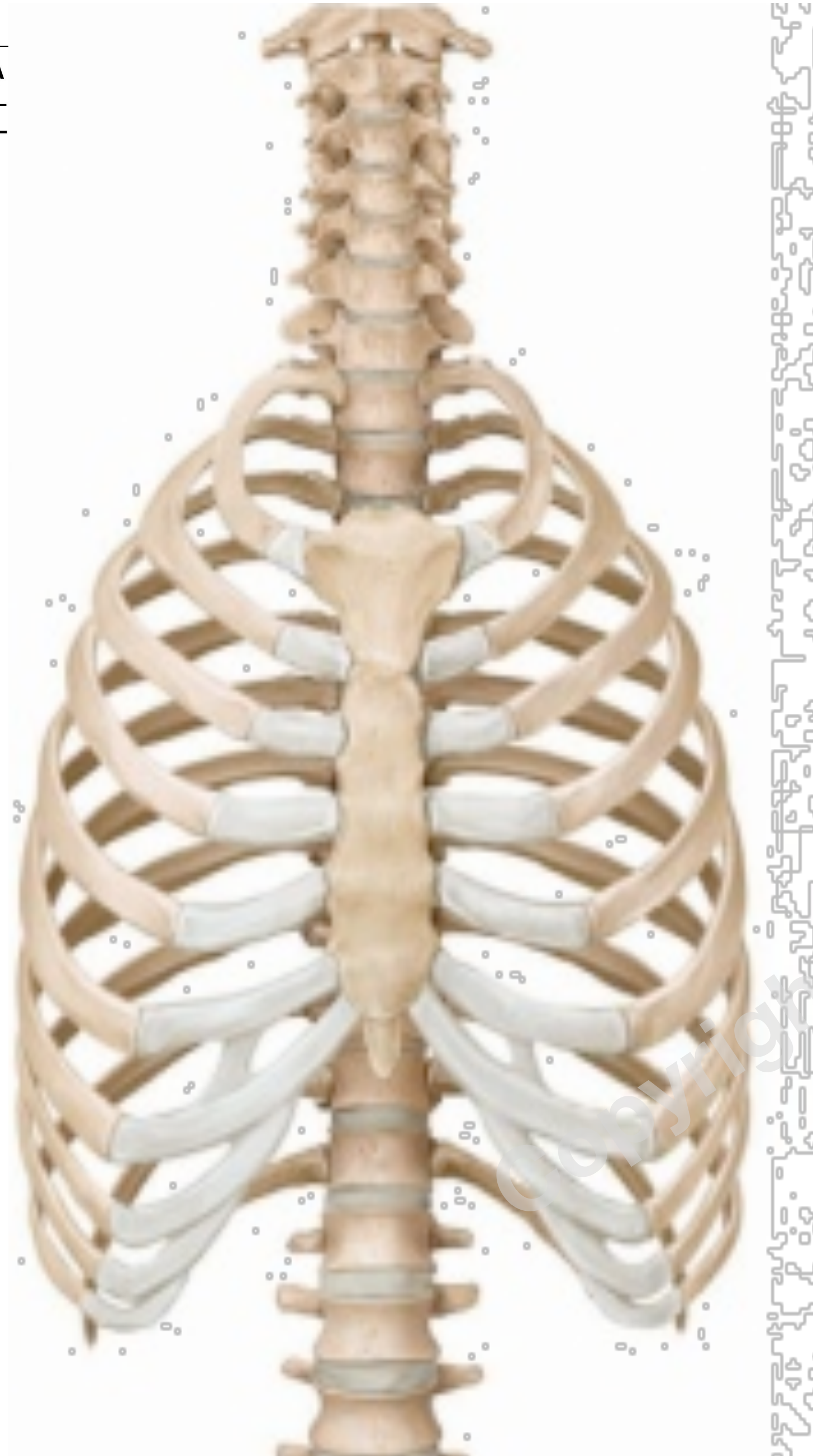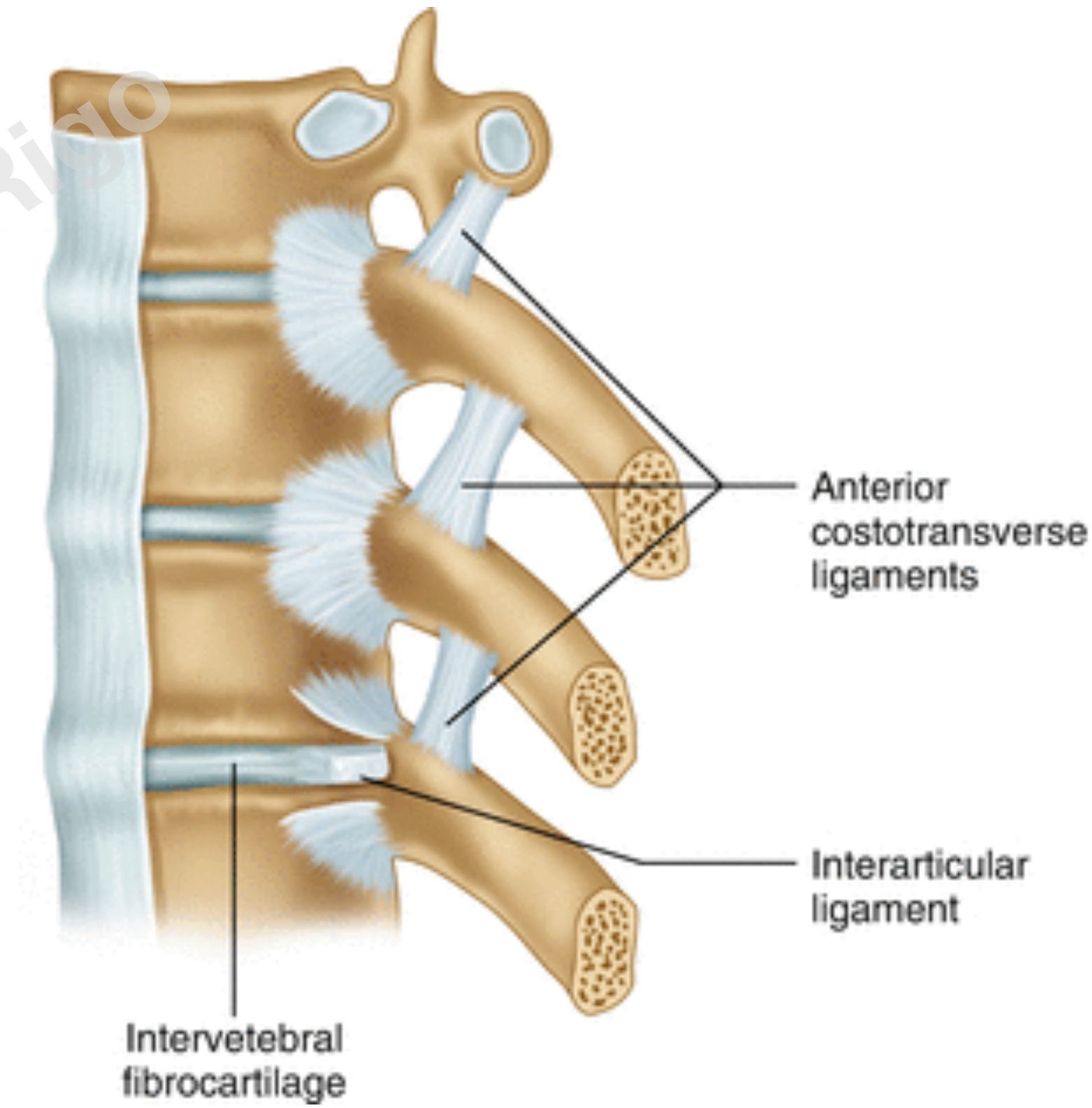
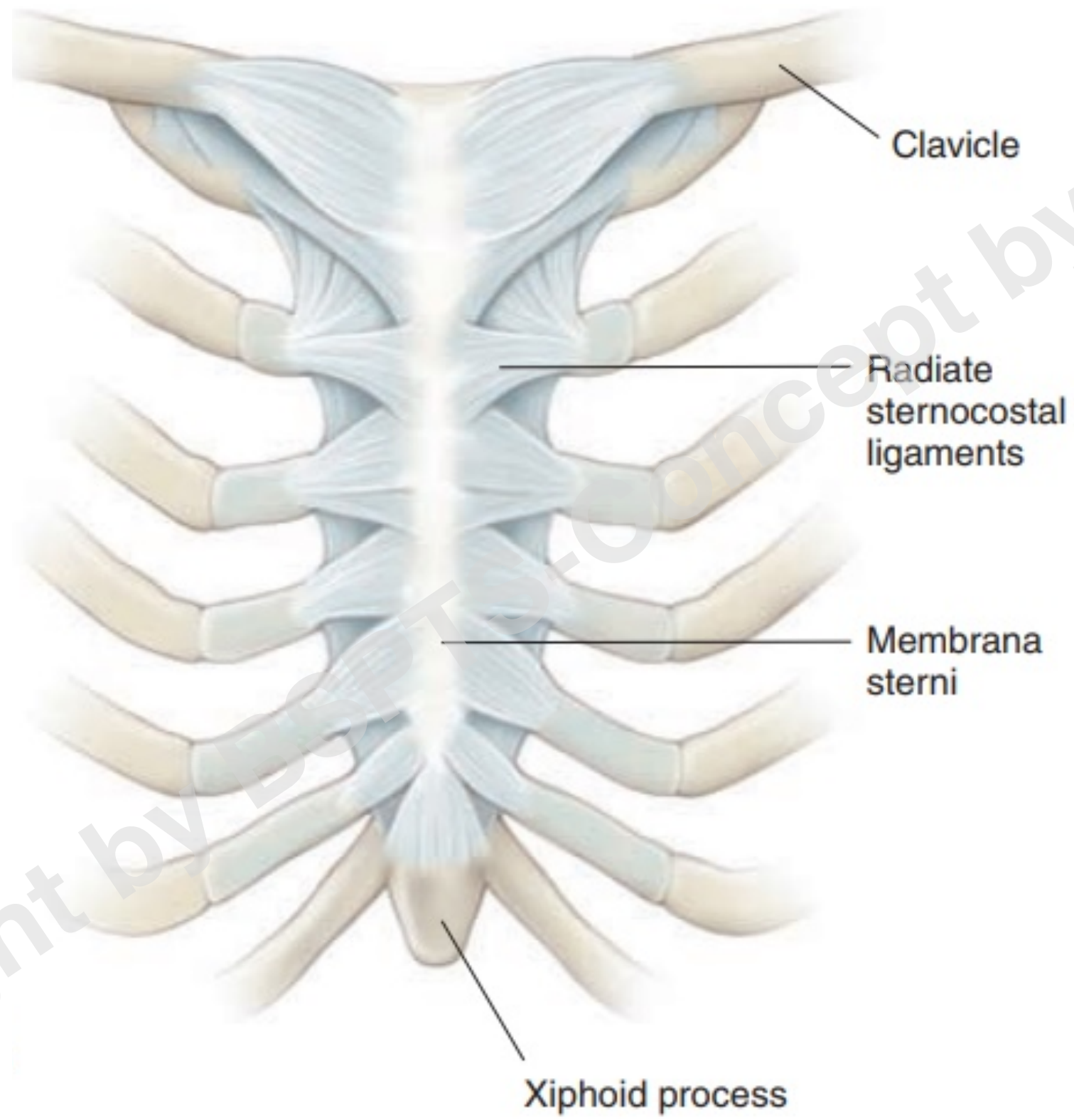
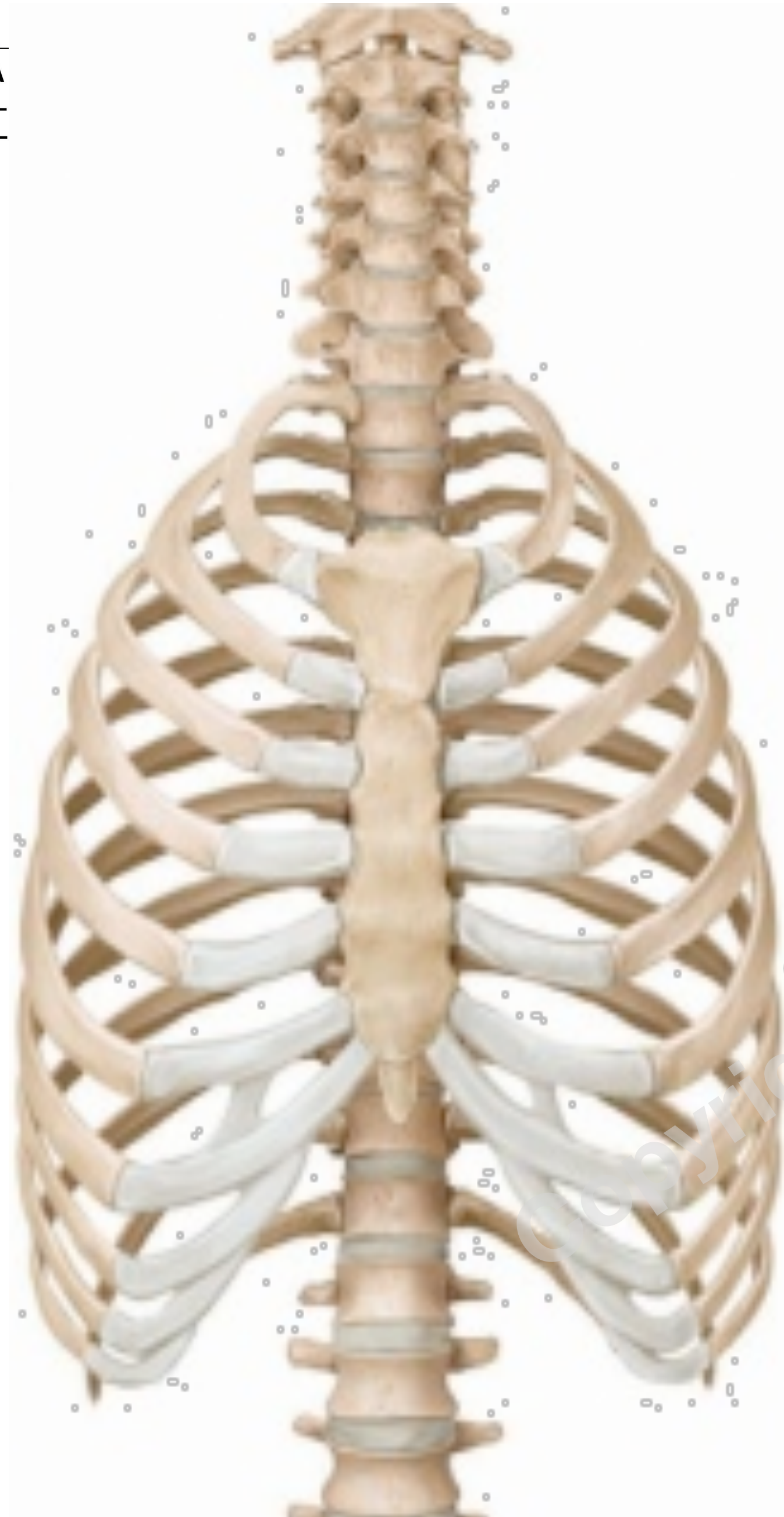


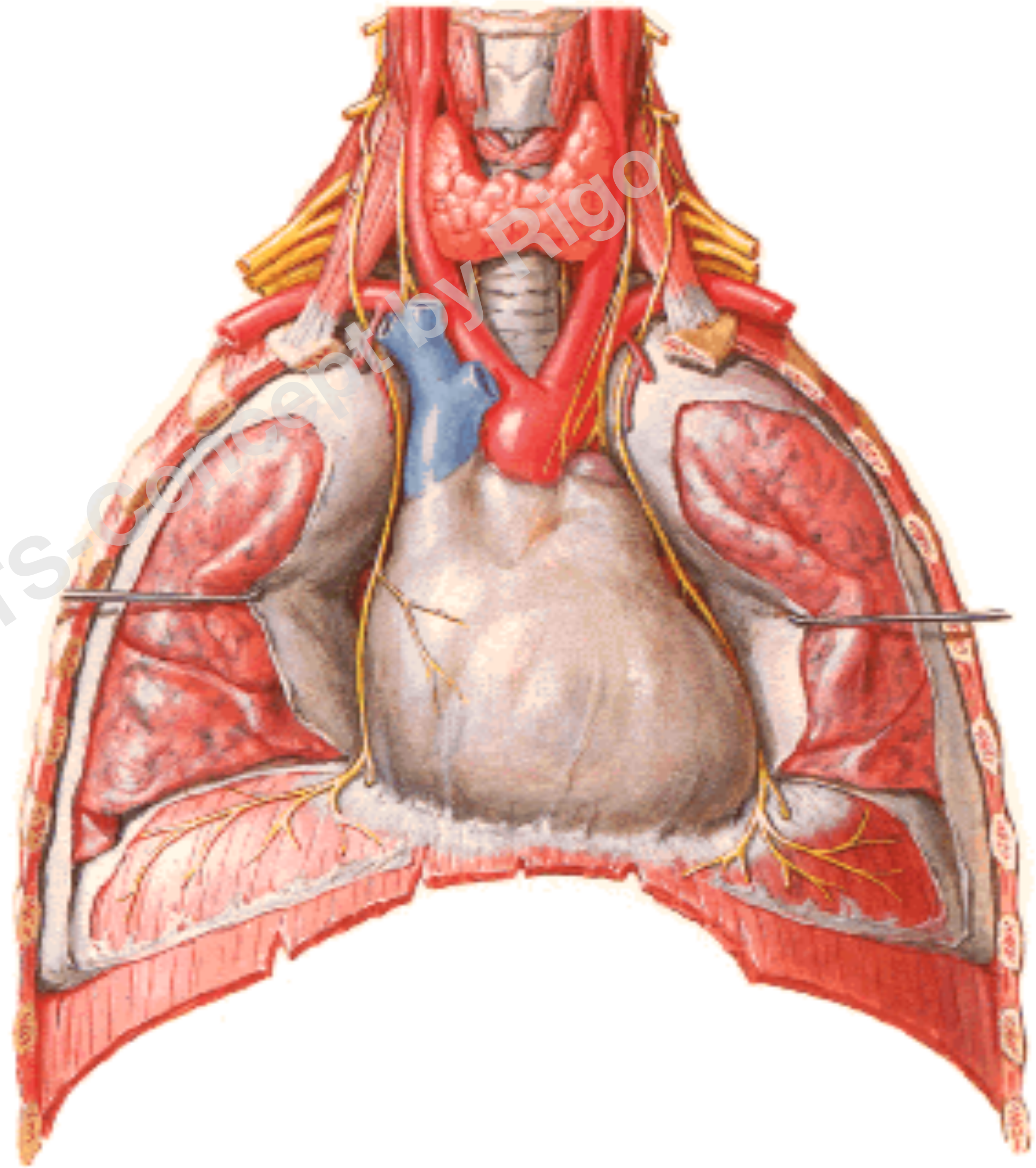
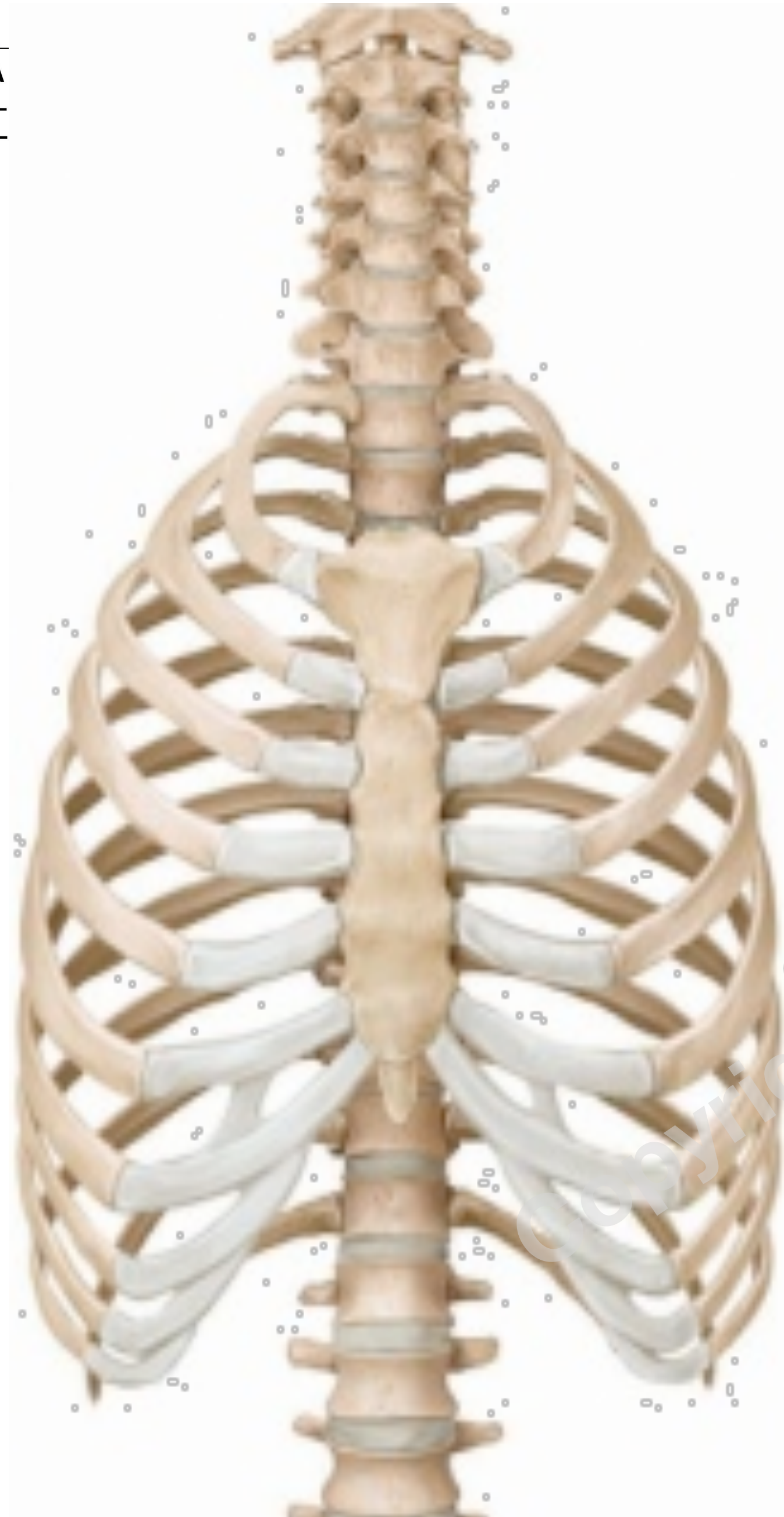
Región Lumbar

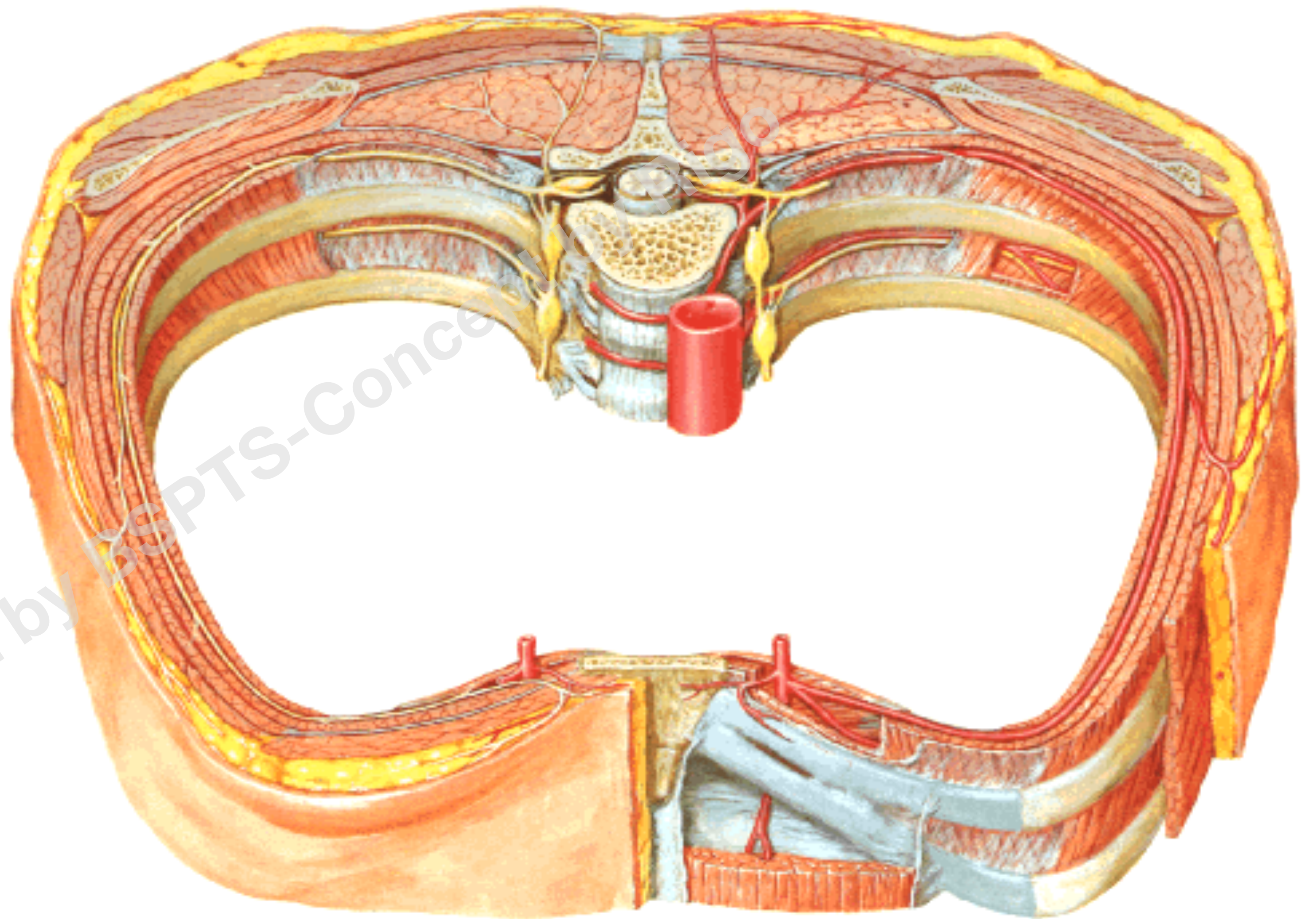
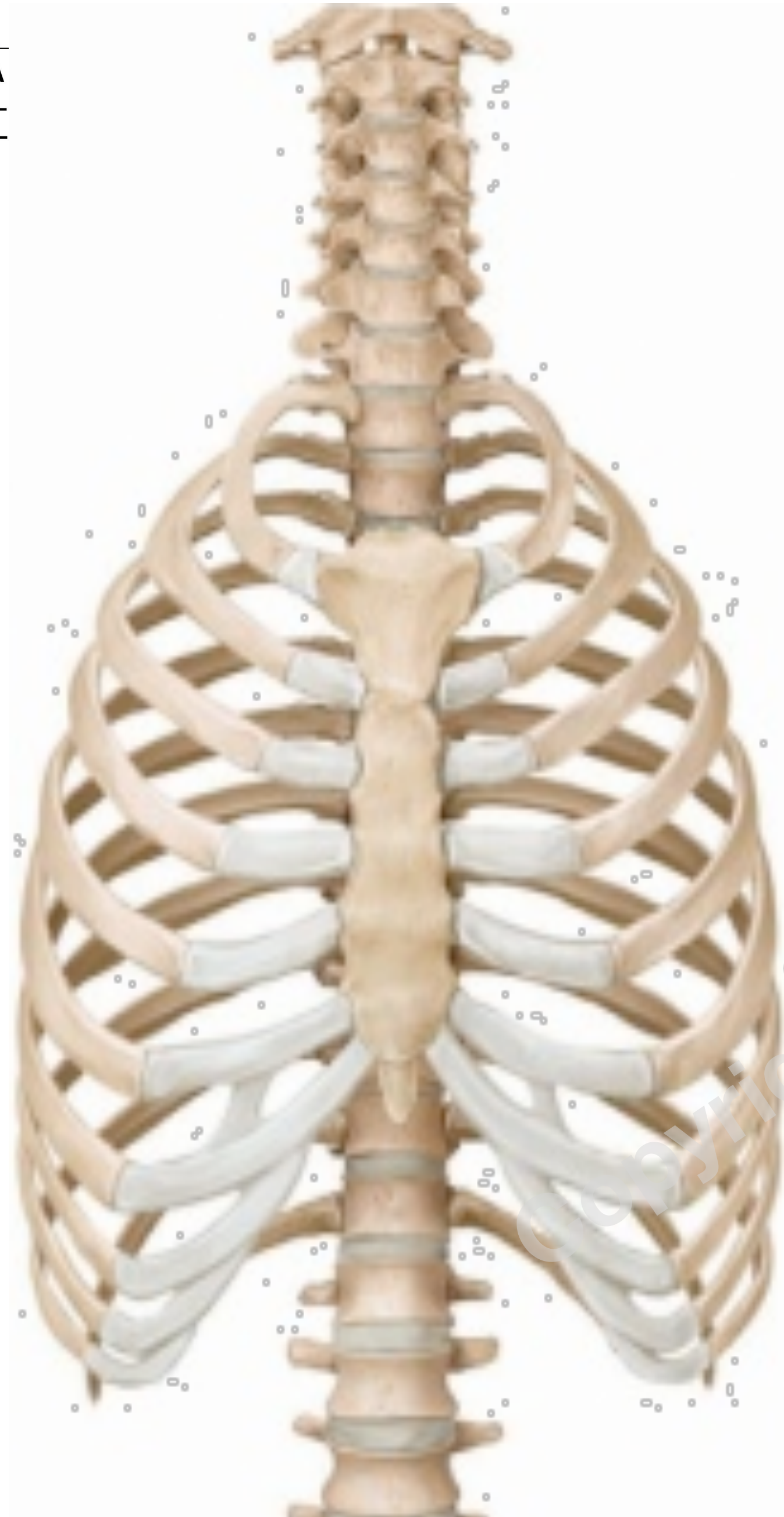
Lordosis Lumbar	
Rectificación	$< 20^\circ$
Normalidad	20-40
Hiperlordosis lumbar	> 41

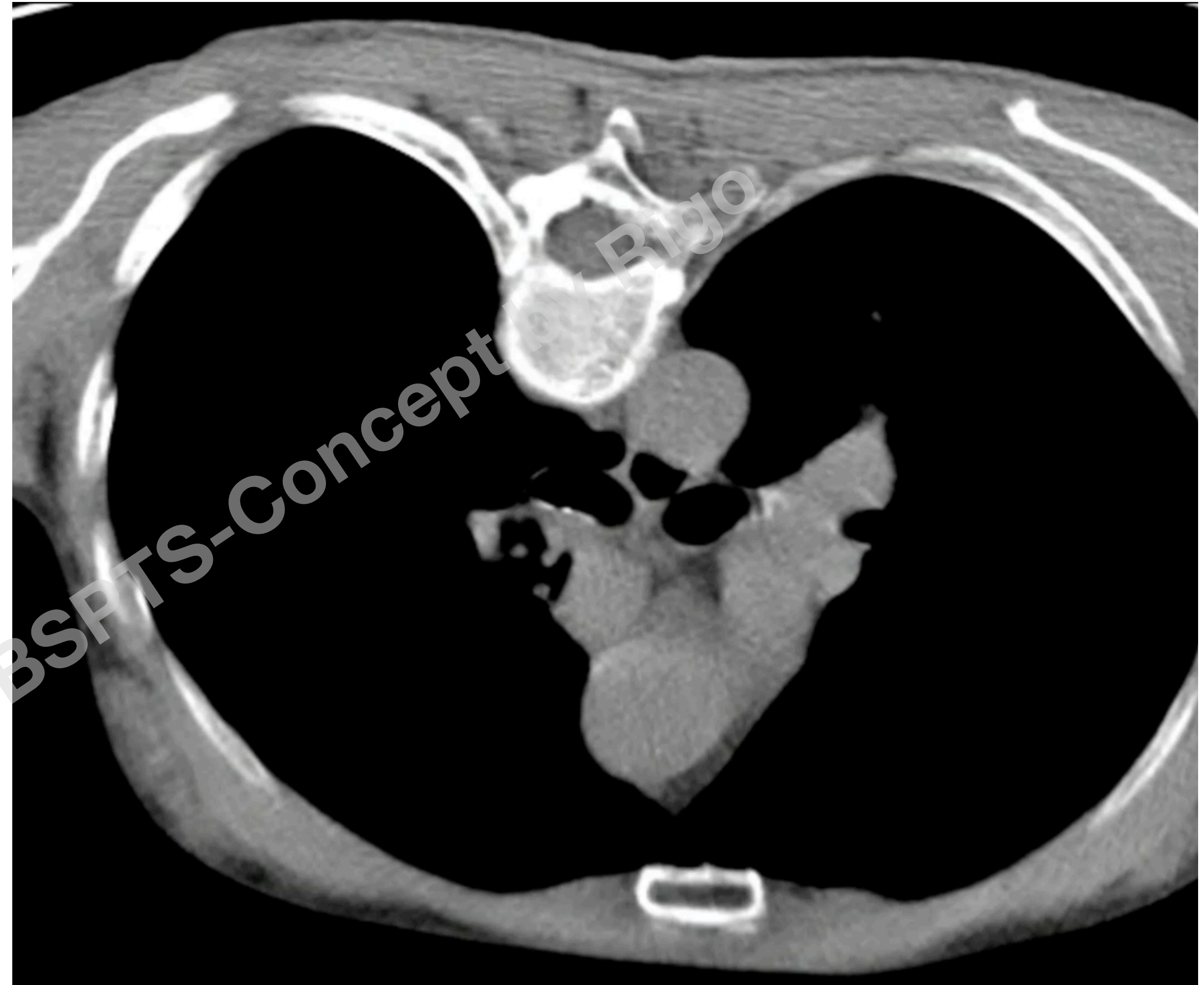
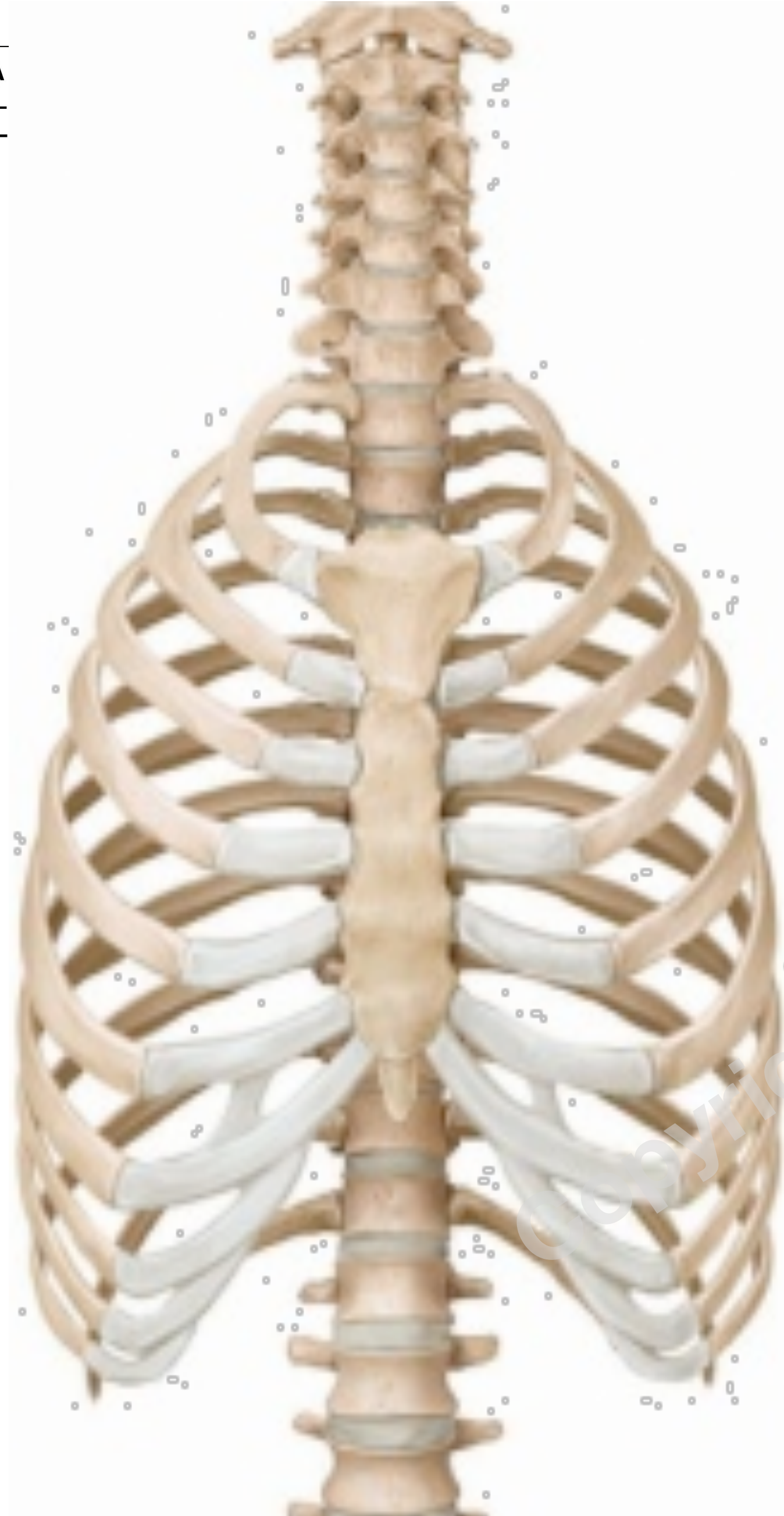












Anatomía de la Columna Vertebral

Planos y Ejes